

UNIT OF AXIS JOURNALS

International Peer Reviewed Medical Journal Committed for Excellence

Treacher -Collins syndrome

Lavanya K Sarella¹Prabodh K Dakey,² Kamala C³

I/C Professor,^{1,2} Resident³

Department of Obstetrics & Gynecology,^{1,3} Department of Orthopedics²

¹⁻³Rangaraya Medical College, Kakinada, Andhra Pradesh, India.

CASE REPORT

ABSTRACT

INTRODUCTION

Treacher Collins syndrome (TCS) is a rare syndrome inherited as autosomal dominant. The affected children may vary in severity ranging from minimal features as slanting of palpebral fissures to major features of craniofacial development such as hypertelorism, micrognathia, maxillary hypoplasia, high arched palate, conductive hearing loss, external ear abnormalities and narrow nostrils. We report a case of Treacher Collins syndrome with term gestation with polyhydramnios and fetus with micrognathia on ultrasound examination with previous two babies and father having the same disorder.

Case Report

A 30 year old ,unbooked G₃ P₂ L₁D₁, postcesarean pregnancy, term gestation with polyhydramnios with breech presentation with features of TCS admitted for institutional delivery at Government General Hospital, Kakinada, Andhra Pradesh, India. Her scan on admission revealed single fetus in breech presentation with micrognathia and AFI 25cm. she delivered a live male baby weighing 2.2kg with features of TCS through ceserean section and inspite of airway support the baby died on first postnatal day.

Conclusion

This case report confirms the need to identify the antenatal women with physical malformations and early ultrasound scan in women with previous H/O anomalous children, and polyhydramnios so that termination can be planned early.

Key Words

Polyhydramnios , Treacher Collins Syndrome, Micrognathia, Anti mongoloid slant of eyes

Received on 30 Oct 2014

Accepted on 25 Nov 2014

Published on 30 Nov 2014

INTRODUCTION

Treacher Collins Syndrome (TCS) is an autosomal dominant disorder first described by Dr.Treacher Collins, a British Ophthalmologist in 1900 but the first extensive description of the condition was produced by Franceschetti and Klein in 1949, who used the term mandibulofacial dysostosis.¹The incidence varies between 1:10,000and 1:50,000.^{2,3} TCS affects the development of structures derived from the first and second branchial arches during early embryonic development.⁴Each child of an individual with TCS has a 50% chance of inheriting the mutation and the children may be affected in varying degrees. Diagnosis is mainly based on clinical features and radiographic findings. The clinical features include antimongoloid slant of palpebral fissures,

hypertelorism, external ear abnormalities, auditory canal abnormalities, conductive hearing loss, micrognathia, maxillary hypoplasia, high arched palate and narrow nostrils.

CASE REPORT

A 30year old G₃ P₂ L₁ D₁ with term gestation belonging to low socioeconomic status was admitted in antenatal ward in view of post caesarean pregnancy in Government General Hospital, Kakinada, Andhra Pradesh, India. She was married for six years, a non-consanguineous marriage. Obstetric history revealed delivery of a live male baby weighing 2kg with facial anomalies in first pregnancy, died after one month due to respiratory problems. The second pregnancy

ended in an emergency caesarean section for cephalopelvic disproportion and a live female baby of weight 3kg was delivered. This baby now aged about 3years is having facial anomalies like low set ears, maxillary and mandibular hypoplasia, right external auditory canal atresia and conductive deafness. Both the pregnancies were full term without complications in the antenatal and postnatal periods. In the present pregnancy she had two antenatal checkups and did not undergo any ultrasound scans till admission. On examination she was ill built and moderately nourished with antimongoloid slant of palpebral fissures, maxillary and mandibular hypoplasia, high arched palate, low set ears with complete left auditory canal atresia and partial atresia of right auditory canal with conductive deafness.

Systemic examination was normal. On abdominal examination the uterus was over distended with polyhydramnios and a single, mature fetus in breech presentation with fetal heart sounds 138/min. Haematological investigations and renal profile was normal. Ultrasound revealed a single live fetus of 35 wks with BPD 9mm, FL 6.7mm in breech presentation showing micrognathia. AFI 25cm and grade III placenta. Elective lower segment caesarean section was done. A live male baby weighing 2.2 kg with features of TCS was born and admitted in NICU with airway support. The baby died on 1st postnatal day due to respiratory problems. The patient's father was also having the features of TCS.



Fig 2:Father




Fig:3 Daughter

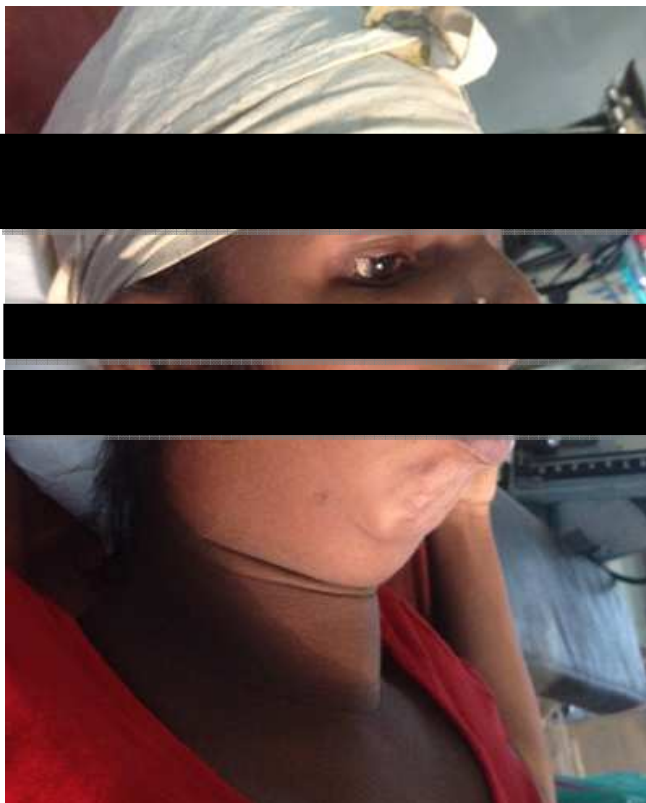

Fig1: Patient with TCS

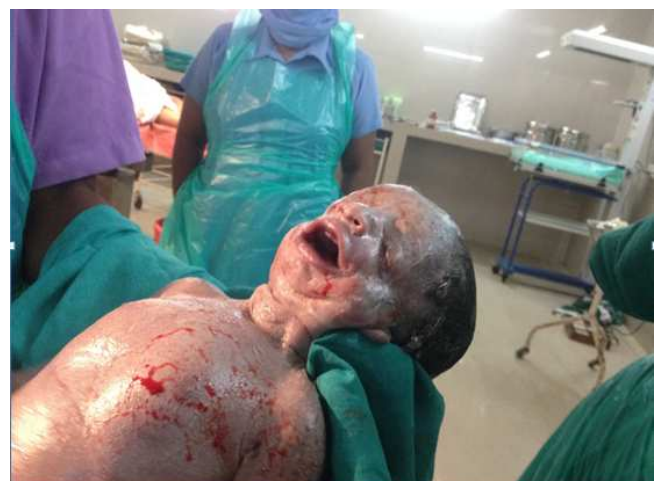

Fig 4: New born

DISCUSSION

TCS is an autosomal dominant disorder where 40% of the affected patients have previous family history and the remaining 60% of cases arising as a result of a denovo mutation. TCOF1 is the only gene currently known to be associated with TCS. It has been postulated that TCS represents a defect of blastogenesis that could be attributed to interference in cephalic neural crest cell histodifferentiation.¹ Prenatal testing of the disease can be done by---

Molecular genetic testing: DNA analysis of fetal cells by aminocentesis at 15-18 weeks of gestation or chorion villous sampling at 10-12 weeks of gestation to detect TCOF1.

Ultrasound: In pregnancies at risk finding of polyhydramnios, microcephaly and abnormal facial features is possible.⁵

Preimplantation genetic diagnosis: in families where disease causing mutation has been identified in an affected family member.

In new born with TCS airway management is required because of narrowing of the airway and severe micrognathia. Neonatal death is usually associated with obstructive sleep apnea as a result of malformations. If after delivery, early diagnosis allows treatment to improve aesthetic appearance, it improves the social life of affected individuals.⁶

CONCLUSION

This case suggests the importance of having awareness of physical abnormalities and early ultrasound scanning in affected members of TCS so that termination can be planned early.

REFERENCES

1. Horiuchi K, Ariga T, Fujioka H, Kawashima K, Yamamoto Y, Igawa H, et al. Mutational analysis of the TCOF1 gene in 11 Japanese patients with Treacher Collins Syndrome and mechanism of mutagenesis. *Am J Med Genet A* 2005; 134:363-7.
2. Argenta LC, Iacobucci JJ. Treacher Collins Syndrome; present concepts of the disorder and their surgical correction. *World J Surg* 1989; 13:401-9 [PUBMED:2773500]
3. Gorlin RJ, Cohen MM, Hennekam RCM. Syndrome of Head and neck, 4th ed. Oxford University Press, Oxford 2001.
4. Atlas of Genetic diagnosis and counselling, Harold chen, MD, FAPP, FACMG, Professor of Paediatrics, Obstetrics and Gynecology and Pathology, Louisiana State University Health Science centre, Shreveport, LA. Humana press, Totowa, New Jersey 2006; 967-71
5. Rotten D, Levallant JM, Martinez H, Ducou le Pointe H, Vicaut E. The fetal mandible: a 2D and 3D sonographic approach to the diagnosis of retrognathia and micrognathia. *Ultrasound ObstetGynecol* 2002; 19:122-30
6. Montoya Perez LA, Arenas Sordo Mde L, Hernandez Zamora E, Aldape Barrios BC. Oral pathology in a group of Mexican patients with genetic diseases. *Med Oral Patol Oral Cir Bucal* 2007; 12:E92-5.

CORRESPONDENCE ADDRESS

Dr. Lavanya kumari sarella MD

I/C Professor of Obstetrics & Gynecology

Rangaraya Medical College, Kakinada

Andhra Pradesh, India.

Email: lavanyakumarisarella@yahoo.com

Please cite this paper as: Lavanya K Sarella, Prabodh K Dakey, Kamala C. Treacher -Collins syndrome. *Inter J Medical Sci Res Prac* 2014; 1 (3): 105-107.

ACKNOWLEDGEMENTS

Nil

PEERREVIEW

Double Blinded externally peer reviewed.

CONFLICTS OF INTEREST

Nil

FUNDING

Nil